

# More Milk, Stronger Teeth? (Part II)

**Bovine milk and breast milk are generally regarded as being protective against caries, mainly due to the high calcium and phosphate content, and the buffering activity of the protein in the milk. Breast feeding is the ideal stimulus for the physiological development of both the muscular and skeletal components of the cranio-facial complex. Lack of intensive breast feeding may lead to a non-nutritive sucking habit, which is responsible for some forms of malocclusion in infancy, especially open-bite and posterior cross-bite.**

In Part I of this article, the authors reviewed the relationship between the various feeding methods and early childhood caries (ECC). The influence of feeding on malocclusion problems will be presented and explained in the beginning of Part II because the type of feeding and the duration of breast feeding have been implicated as possible causes of deleterious oral habits. Respiration, swallowing, mastication and speech articulation are functions that develop during breast feeding and any imbalance in these systems may lead to sucking that fails to satisfy the infant and to the acquisition of deleterious oral habits. Sucking habits that continue beyond 24 months of age may result in an increased overjet, decreased maxillary and increased mandibular inter-canine widths, and an associated increased risk for posterior crossbite.<sup>1</sup>

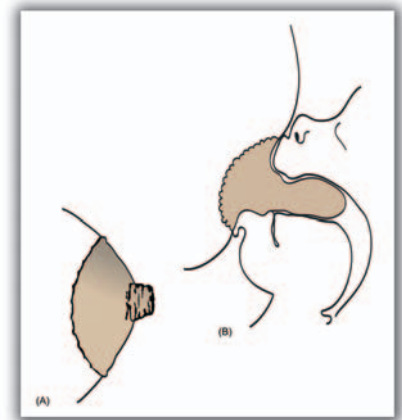
Different types of sugar can produce different amounts of organic acid; sucrose is the most cariogenic and lactose is the least. Several *in vitro* studies and animal experiments have shown that milk is not cariogenic.<sup>2,4</sup> A human observational study also reported an inverse relationship between milk consumption and dental caries increment.<sup>5</sup> Conversely, negative features of milk have also been described. It has been shown that the acidity of human dental plaque increased after the frequent use of either lactose or milk.<sup>6</sup> However, one human experimental study revealed that, although milk is slightly acidogenic in plaque, it produces less acid than lactose or sucrose alone.<sup>7</sup> By reviewing and analysing the scientific evidences of these controversies, the second objective of this article is to address the cariogenicity and/or cariostatic effect of bovine milk and human breast milk.

## Feeding & Malocclusion

Knowledge of the benefits of breast feeding in dentistry is of

importance, since breast feeding is a protective factor against some types of malocclusion.<sup>8</sup> The theoretical mechanisms relate to the cranio-facial musculature and skeletal development which are differently influenced if a child is bottle fed or exclusively breast fed. The mechanism of sucking is different in the two instances.<sup>9</sup> When breast feeding the child obtains milk by drawing both the nipple and part of the areola into the mouth, see figure 1. The movement of the lips and tongue contribute more to squeezing than to sucking. The infant's lips squeeze the areola where the mother's lactiferous sinuses are located, and the tongue compresses the soft breast nipple against the palate using a peristaltic-like motion.

By contrast when bottle feeding the child uses the tongue with a piston-like motion in order to compress the artificial nipple against the palate. During this action there is a more powerful sucking activity generated by the lips and cheeks. In addition, the different modes of feeding have different impacts on the palate. The more resistant consistency of the artificial nipple, compared to breast nipple, causes a greater upward force, to which the tongue adds an additional



**Figure 1** The breast and nipple (a) prior to and (b) during breast feeding, showing the position of the tongue and the presence of part of the areola in the oral cavity

pushing action with the piston-like movement aimed at squeezing out milk,<sup>9</sup> see figure 2.

Early introduction of bottle feeding induces a pattern of low-impact muscular activity, different involvement of the cranio-facial muscles, and hence different forces on the palate; all of which may interfere with the normal development of the alveolar ridges and transversal growth of the hard palate, and therefore may lead to a posterior crossbite.<sup>10</sup>

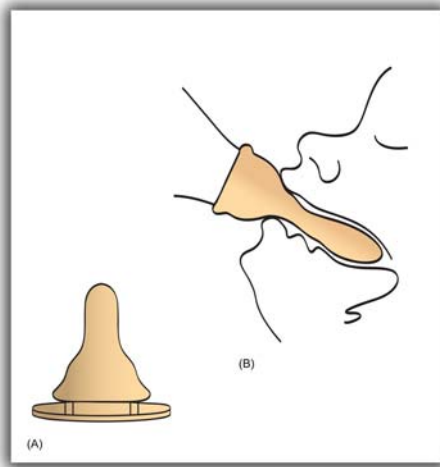


Figure 2 The artificial nipple (a) prior to and (b) during bottle feeding, showing the resistant consistency of the artificial nipple

**Feeding, Deleterious Oral Habits & Malocclusion**

Breast feeding is the natural and most acceptable method of nursing a baby. However, in many developed and developing countries, on demand breast feeding has become less popular, and conversely non-nutritive sucking habits have become more frequent. To calm a worried child, to reduce pain or hunger, or to induce sleep, the child was, in the past, often given a wad, dampened with sugar, honey, and/or milk.<sup>11</sup> In the late 18<sup>th</sup> century the traditional 'on-demand' breastfeeding started to be modified to become a scheduled activity of four to six times a day. At the same time artificial feeding became increasingly popular. Unfortunately, with these changes children have less opportunities to naturally satisfy their sucking urge.

During breast feeding, most of the milk is obtained during the first five to six minutes; however, the infant often wants to suck for 15 to 40 minutes.<sup>12</sup> Moreover, the baby's sucking urge increases with time and busy modern mothers can find it difficult to find the time to satisfy their child's urge.<sup>13</sup> Consequently, opportunity for unrestricted or non-nutritive breast sucking is lost. As a result, the surplus sucking urge may be either frustrated or re-channeled. The child may then adopt digit sucking to obtain satisfaction, or the mother may provide a pacifier.

A number of studies have indicated that there is an increased incidence of malocclusion in children with persistent non-nutritive sucking habits.<sup>14-16</sup> A typical clinical outcome of a digit

sucking habit is an anterior open-bite, as well as an increased overjet which results from the labial inclination of the maxillary incisors. According to Bowden,<sup>17</sup> the proportion of Skeletal Class II relationships is higher among the digit suckers (40%) and the pacifier suckers (35%) than among children without non-nutritive sucking habits (29%).

The effect of the pacifier on the incisor relationship is of interest because even the lightest pressure created by a flat artificial nipple can create an open-bite. For the relationship between the pacifier sucking habit and cross-bite, the hypothesis is as follows. The pacifier is not always sucked for the whole day, but often stays in the mouth passively. The tongue occupies a lower position in the anterior part of the mouth, so reducing the palatal support of the maxillary primary canines and molars against the pressure of the cheeks. The tongue then exerts an increased lateral pressure on the mandibular canines and first molars, see figure 3. The lack of palatal support from the tongue results in a narrower maxillary arch, and the pressure created the tongue widens the mandibular arch. Both of these changes synergistically act to create a transverse disharmony, which raises the tendency for a posterior cross-bite to develop.<sup>18</sup>

Since there is an inherent need for non-nutritive sucking in order to provide comfort for infants, any recommendations to cease non-nutritive sucking habits prior to 24 months of age may be deemed to be unwarranted and unrealistic.

Although trends within society often swing from one extreme to another over the years, today's professionals should realize that the lack of intensive breast feeding is the prime reason for the development of digit and pacifier sucking.

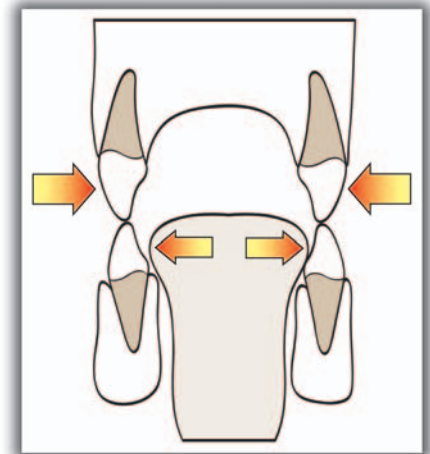


Figure 3 Transversal disharmony in the canine region due to lower position of the tongue in pacifier suckers

**Cariogenicity of Bovine Milk**

Milk is a complex solution which contains lactose, calcium, phosphorus, proteins, fat and vitamins. Some of the constituents of bovine milk might be expected to favor caries while others might hinder it. Bovine milk consists of 3-4%

lactose. Laboratory studies have shown that lactose, which is a disaccharide, is composed of glucose and galactose, produces dental caries when fed to animals because it enhances the oral implantation of cariogenic bacteria in animals, and produces decalcification of tooth enamel when acted upon by bacteria.<sup>19</sup> Bovine milk is thus implicated in the production of ECC by virtue of the lactose content. However, it is noteworthy that streptococci can only increase lactose fermentation after frequent contact with bovine milk.<sup>20</sup>

Although lactose solutions can produce a rapid pH drop of in human dental plaque,<sup>6</sup> bovine milk is generally regarded as being protective against caries, mainly due to the high calcium and phosphate content, and also because of the buffering activity of the milk protein.<sup>21</sup> In an *in vitro* study of plaque pH measurements with an antimony electrode, Jenkins and Ferguson showed that while milk carbohydrate can be utilized by salivary bacteria for acid production, the pH values are higher than with a 4% lactose control solution after 4 and 24 hours of incubation.<sup>22</sup> Moreover, Weiss and Bibby found that bovine milk contains proteins in the form of casein micelles which allow the formation of stable calcium phosphate complexes. Therefore, they claimed that bovine milk reduced solubility of enamel, regardless of whether or not it is raw, pasteurized, whole or skimmed milk. They also showed that the protective agent in milk reacts rapidly with the enamel and resists washing.<sup>2</sup>

According to those authors, the cariogenic potential of milk, under normal conditions, has no clinical relevance, thus bovine milk does not produce caries and in fact it has a cariostatic action. It is even believed that if milk is taken simultaneously with a caries challenge, such as sucrose, the milk will exert some protection against the cariogenic challenge of the sucrose.<sup>4</sup> However, the addition of sugar to the contents of a feeding bottle appears to be an important factor in the occurrence of ECC, because milk containing sucrose is much more cariogenic than milk alone.<sup>23</sup> Consequently, the practice of adding any sugar to milk should be discouraged. Moreover, the use of bovine milk is not recommended before the first year of life.<sup>24</sup>

### Cariogenicity of Human Milk

The content of human milk differs from that of bovine milk in several ways which are probably significant in terms of cariogenicity, see Table 1. In the various experimental studies that have been conducted, it has been shown that human milk depresses plaque pH to a greater extent, and it is less able to limit enamel dissolution than bovine milk.<sup>20,21</sup> The greater amount of calcium that dissolves in human milk/enamel incubates demonstrates the greater cariogenicity or lack of protection against enamel dissolution, compared to bovine milk. This is likely to be due to (i) the higher lactose

www.silfradent.com

THE THOUGHT OF THE DENTIST  
BRINGS A BROAD SMILE.

**silfradent**

Medical Line

S U R G Y B O N E  
M A C H I N E F O R B O N E S U R G E R Y

You can put more smiles of your patients' faces and work with the greatest comfort thanks to **Silfradent** medical instruments. With an appealing design, they are delicate and efficient in delivering dental care.

After a thirty-year experience in dental laboratories, today **Silfradent** manufactures the most innovative dental equipment created to fully meet your professional needs.

Like **Surgybone**, the machine for bone surgery.



CHOOSE SILFRADENT'S EXPERIENCE AND YOU WILL SEE  
A FEELING OF WELL-BEING ON YOUR PATIENTS' FACES

	Energy (Kcal)	Protein (g)	Lactose (g)	Fat (g)	Calcium (mg)	Phosphate (mg)
Human milk	67	1.2	7.0	3.8	36	18
Bovine milk	66	3.3	4.0	3.7	120	95

**Table 1. The energy and nutrient content of human milk and bovine milk per 100ml (adapted from Darke 1976)<sup>33</sup>.**

concentration, (ii) the lower calcium and phosphate concentration, and (iii) the lower protein concentration, which in turn decrease the buffering capabilities and hence the protective effect.<sup>21</sup>

Nevertheless, it has been shown that human milk is not cariogenic because it does not decrease the enamel pH significantly in breastfed infants, and the fermentation of human milk is slower than that of sucrose.<sup>25</sup> Aide from the buffering capacity and the promoting of enamel remineralization, by way of calcium and phosphate deposition on the enamel surface, breast milk is characterized by a complex defense system that inhibits the growth of several microorganisms, including mutans streptococci.<sup>26</sup> The IgA antibodies found in the milk can interfere with the colonization of pioneer streptococci and consequently with the colonization of other bacteria that inhabit the oral cavity.<sup>27</sup> In addition, studies have demonstrated that breast milk reduces the risk of diseases, such as gastroenteritis, infections, asthma, atopic diseases and diabetes mellitus, which have some influence on infant feeding.<sup>28</sup> Therefore, breast milk supposedly protects against caries, due to the reduced development of disorders that contribute to the pathophysiology of caries and due to the reduced use of cariogenic medications.

Although there is no scientific evidence that confirms an association between breastfeeding and ECC, many professionals still express disbelief at the fact that human milk is non-cariogenic. Human milk has been shown to contain a mix of oligosaccharides that are exclusive to the human species, which may act at the initial infectious stage by inhibiting bacterial adhesion to epithelial surfaces.<sup>26</sup> Therefore, the results from studies that used lactose or milk from other animal species should not be extrapolated to breast milk due to its distinct composition. Moreover, it is unlikely that milk accumulates in the infant's mouth during breast feeding because, as explained earlier, the nipple and part of the areola occupy a greater volume of the oral cavity during breast feeding than when an artificial nipple is used on a nursing bottle. This theoretically means that breast feeding does not cause ECC,<sup>29</sup> see figures 1 and 2. Another argument which is commonly expressed in

the literature is that the addition of sucrose to human milk makes it cariogenic.<sup>25,30</sup> This should be a hypothetical statement because, this practice would hardly ever happen unless during breast feeding the infant is offered a sweetened drink, or sucrose is added to previously expressed breast milk.

Since the 1980s, favorable evidence supporting the practice of breastfeeding has increased considerably. Breastfed children are said to be more intelligent because breast milk contains some long chained fatty acids which are found in the human brain.<sup>31</sup> Breast milk also helps ensure proper growth and development of the child, whilst also strengthening the mother/child bond.<sup>32</sup> These findings serve to demonstrate the excellent nutritional and psychological benefits that are provided by breast feeding. Based on scientific evidence, the World Health Organization (WHO) recommends the exclusive practice of breast feeding for the first six months of life and its continuance, accompanied by adequate complementary foods, until the age of two years or beyond.

In Part III of this series it is proposed to consider the cariogenicity of infant formulas, fluoridated milk and other milk based products. **DA**

**References**

1. Tomit NE, Bijella VT, Franco LJ. The relationship between oral habits and malocclusion in preschool children. *Rev Saude Publica.* 2000;34:299-303.
2. Weiss ME, Bibby BG. Effects of milk on enamel solubility. *Arch Oral Biol.* 1966;11: 49-57.
3. Birkhed D, Imfeld T, Edwardsson S. pH changes in human dental plaque from lactose and milk before and after adaptation. *Caries Res.* 1993;27:43-50.
4. Seow WK, Amaratunge A, Sim R, Wan A. Prevalence of caries in urban Australian Aborigines aged 1-3.5 years. *Pediatr Dent.* 1999;21:91-6.
5. Mor BM, Mc Dougall WA. Effects of milk on pH of plaque and salivary sediment and the oral clearance of milk. *Caries Res.* 1977;11:223-30.
6. Birkhed D, Ohlsson A, Svensson C, Edwardsson S, Imfeld T. Milk and lactose acid production in human dental plaque. *J Dent Res.* 1981;60: 1245.
7. Palmer B. The influence of breastfeeding on the development of the oral cavity: a commentary. *J Hum Lact.* 1998;14:93-8.
8. Search&itool=pubmed\_AbstractPlus&term=%22Viggiano+D%22%5BAuthor%5D" \o "Click to search for citations by this author." Viggiano D, 22%5BAuthor%5D" \o "Click to search for citations by this author." Fasano D, \o "Click to search for citations by this author." Monaco G, \o "Click to search for citations by this author." Strohmenger L. Breast feeding, bottle feeding, and non-nutritive sucking; effects on occlusion in deciduous dentition. *Arch Dis Child.* 2004;89(12):1121-3.
9. ool=pubmed\_docsum" Karjalainen S, Ronning O, Lapinleimu H, Simell O. Association between early weaning, non-nutritive sucking habits and occlusal anomalies in 3-year-old Finnish children. *Int J Paediatr Dent.* 1999;9(3):169-73.
10. Levin S. Dummies. *S Afr Med J.* 1971;45:237-40.
11. Levy DM. Thumb and finger sucking from the psychiatric angle. *Angle Orthod.* 1937;8:100-3.

12. Gray SJ. Correlates of breastfeeding frequency among nomadic pastoralists of Turkana, Kenya: a retrospective study. *Hysial Anthr.* 1995;98:239-55.
13. Bowden BD. A longitudinal study of the effects of digit- and dummy-sucking. *Am J Orthod.* 1966;52:887-901.
14. Farsi NM, Salama FS. Sucking habits in Saudi children: prevalence, contributing factors and effects on the primary dentition. *Pediatr Dent.* 1997;19:28-33.
15. Adair SM, Milano M, Lorenzo I, et al. Effects of current and former pacifier use on the dentition of 24- to 59-month-old children. *Pediatr Dent.* 1995;17:437-44.
16. Weber F, Woolridge MW, Baum JD. An ultrasonographic study of the organisation of sucking and swallowing by newborn infants. *Dev Med Child Neurol.* 1986; 28: 19-24.
17. Ogaard B, Larsson E, Lindsten R. The effect of sucking habits, cohort, sex, intercanine arch widths, and breast or bottle feeding on posterior crossbite in Norwegian and Swedish 3-year-old children. *Am J Orthod Dentofacial Orthop.* 1994;105:161-6.
18. Abbey LM. Is breast feeding a likely cause of dental caries in young children? *J Am Dent Assoc.* 1979;98:21-3.
19. Ripa LW. Nursing habits and dental decay in infants: "nursing bottle caries". *ASDC J Dent Child.* 1978;45:274-5.
20. Bowen W.H. Effect of milk on cariogenesis. *Caries Res.* 1993;27:461-6.
21. Rugg-Gunn AJ, Roberts GJ, Wright WG. Effects of human milk on plaque pH in situ and enamel dissolution in vitro compared with bovine milk, lactose, and sucrose. *Caries Res.* 1985;19:327-34.
22. Jenkins GN, Ferguson DB. Milk and dental caries. *Br Dent J.* 1966;120: 472-7.
23. American Academy of Pediatrics. Work Group on Breastfeeding. Breastfeeding and the human milk. *Pediatrics.* 1997;100:1035-9.
24. Maslak EE, Afonina IV, Kchmizova TG, Litovkina LS, Luneva NA. The effect of a milk fluoridation project in Volgograd. *Caries Res.* 2004;38(4):377.
25. Kunz C, Rodrigues-Palmero M, Koletzko B, Jensen R. Nutritional and biochemical properties of human milk, Part I: General aspects, proteins, and carbohydrates. *Clin Perinatol.* 1999;26:307-33.
26. Marcotte H, Lavoie MC. Oral microbial ecology and the role of salivary immunoglobulin A. *Microbiol Mol Biol Rev.* 1998;62:71-109.
27. \1 "autor1#autor1" Ribeiro NME, \1 "autor2#autor2" Ribeiro MAS. Breastfeeding and early childhood caries: a critical review. *J Pediatr (Rio J).* 2004;80(5 Suppl):S199-210.
28. Caufield PW, Griffen AL. Dental caries. An infectious and transmissible disease. *Pediatr Clin North Am.* 2000;47: 1001-19.
29. Mortensen EL, Michaelsen KF, Sanders SA, Reinisch JM. The association between duration of breastfeeding and adult intelligence. *JAMA.* 2002;109:1044-53.
30. Rugg-Gunn AJ, Hackett AF, Appleton DR, Jenkins GN, Eastoe JE. Relationship between dietary habits and caries increment assessed over two years in 405 English adolescent schoolchildren. *Arch Oral Biol.* 1984;29:983-92.
31. Pollock JJ. Long-term associations with infant feeding in a clinical advantaged population of babies. *Dev Med Child Neurol.* 1994;36:429-40.
32. Erickson PR, Mazhari E. Investigation of the role of human breast milk in caries development. *Pediatr Dent.* 1999;21:86-90.
33. Darke SJ. Human milk versus cow's milk. *J Hum Nutr.* 1976;30(4):233-8.



Professor Nigel M. King is a Professor in Paediatric Dentistry in the Faculty of Dentistry at The University of Hong Kong. He is a Fellow of the Hong Kong Academy of Medicine (Dental Surgery) and the College of Dental Surgeons of Hong Kong and the Royal College of Surgeons of Edinburgh. Currently, he is an examiner for the Royal Australasian College of Dental Surgeons.



Dr Wong Hai Ming obtained her DDS in Taiwan and MDS in England. In 2005, she was awarded a PhD degree from the University of Hong Kong. Dr Wong is now in private practice in Hong Kong. She also lectures part-time at the Faculty of Dentistry, the University of Hong Kong.



Dr Abdul Hakim Ahmad is currently a postgraduate student in Paediatric Dentistry, Faculty of Dentistry, The University of Hong Kong



Dr Prashanth Kumar is currently a postgraduate student in Paediatric Dentistry, Faculty of Dentistry, The University of Hong Kong



Dr Manikandan is currently a postgraduate student in Paediatric Dentistry, Faculty of Dentistry, The University of Hong Kong

# Dental Asia

## Products Supplement —

### The ONLY publication

### that gives you

### information of the latest

### dental products

## DENTAL ASIA

Asia's Premier Journal for Dental Practice and Technology

MCA (P) No: 308-06-2005 KDN: PPS 1482/9-2006 ISSN: 0219-8882 • Company Registration number: 200001473N • WWW.PABLOASIA.COM May / June 2006

**Products Supplement**

<div style="text-align: center;">  </div> <p style="text-align: center; font-weight: bold; font-size: small;">No Resin Auto-Curing Glass Ionomer</p> <p style="font-size: x-small;">Fuji 7 is the world's first conventional auto-curing glass ionomer material that contains NO Resin yet is capable of accelerated setting by light-curing. With 6 times the fluoride release of high strength glass ionomers and antibacterial properties, it offers greater protection to surrounding tooth surfaces.</p> <p style="font-size: x-small;">It is ideal for use in the new treatment concepts of Minimum Intervention Dentistry such as surface-protection of erupting teeth and internal remineralization.</p> <p style="font-size: x-small;">Fuji 7 comes in a special pink or white shades and is available in capsules, powder and liquid forms.</p> <p style="text-align: center; font-size: x-small; background-color: #0056b3; color: white; padding: 2px;">Fax: +65-6546-7577 / www.gcasia.info</p>	<div style="text-align: center;">  </div> <p style="text-align: center; font-weight: bold; font-size: small;">Beautiful Flow</p> <p style="font-size: x-small;">Shofu's new member of the Giomer family – BEAUTIFUL FLOW – is the perfect addition to your range of indications. It is an improvement over its earlier release, Beautiful, which is a true hybridization between glass ionomer and composite resin material with the ability to release and recharge fluoride while providing excellent aesthetics and physical properties. In combination with the Fil-Bond adhesive system, Beautiful Flow allows the dentist to offer his patients a safe, all-round, fluoride-rich material system with an aesthetic solution. Beautiful Flow is available in 6 shades that optimally harmonise with Beautiful.</p> <p style="text-align: center; font-size: x-small; background-color: #0056b3; color: white; padding: 2px;">Fax: +65-6377-1121 / www.shofu.com.sg</p>
<div style="text-align: center;">  </div> <p style="text-align: center; font-weight: bold; font-size: small;">Root Canal Sealer</p> <p style="font-size: x-small;">The root canal sealer Apexil Plus from Ivoclar Vivadent is characterized by its excellent tissue compatibility. The active agent calcium hydroxide promotes a natural balance in the periapical tissue.</p> <p style="text-align: center; font-size: x-small; background-color: #0056b3; color: white; padding: 2px;">Fax: +423-235-3360 / www.ivoclarvivadent.com</p>	<p style="font-size: x-small;">Disorders due to formaldehyde, antibiotics or antihypertensives cannot occur. The new sealer is resorbed only to a minimal extent. It is flowable and slightly expands when the setting procedure takes place.</p> <p style="font-size: x-small;">The root canal system can be permanently sealed. The handy automatic syringe enables a convenient application and the mixed Apexil Plus can be used for over 3 hours.</p>